

## Supplemental Information

### SUPPLEMENTAL METHODS

#### Index Test (MMBV)

As detailed in the Instructions for Use, the intended use of MMBV is in conjunction with clinical assessments and other laboratory findings as an aid to differentiate bacterial from viral infection. The test is indicated for hospital admitted patients, and patients presenting to the emergency department, urgent care center who have exhibited symptoms of acute infectious disease for less than 7 days and experienced fever within the last 7 days. The test has not been studied in patients <90 days old, and patients with 1 or more of the

following conditions: Suspicion and/or confirmed diagnosis of infectious gastroenteritis/colitis; Active inflammatory disease; Congenital or acquired immune deficiency; Chronic fungal or parasitic infection; Infection with HIV; Hepatitis B virus (HBV); Hepatitis C virus (HCV); Infection with active tuberculosis (TB); Significant trauma or burns in the last 7 days; Patients who have undergone major surgery in the last 7 days; Pregnant women; Active malignancy. The test is not intended as a standalone diagnostic test, is not intended to identify specific pathogens or predict disease course and is not intended to distinguish between infectious and non-infectious etiologies.



## Requisition Form 1- after initial assessment

---

#### GENERAL INFORMATION

Physician name: \_\_\_\_\_

Date/Time: \_\_\_\_\_

Patient study number \_\_\_\_\_

---

#### PATIENT DIAGNOSIS

1. Suspected clinical syndrome:
  - Fever without source (FWS)
  - Upper respiratory tract infection (URTI)
  - Lower respiratory tract infection (LRTI)
  - Urinary tract infection (UTI)
  - Gastrointestinal infection (GI)
  - Other (please specify): \_\_\_\_\_

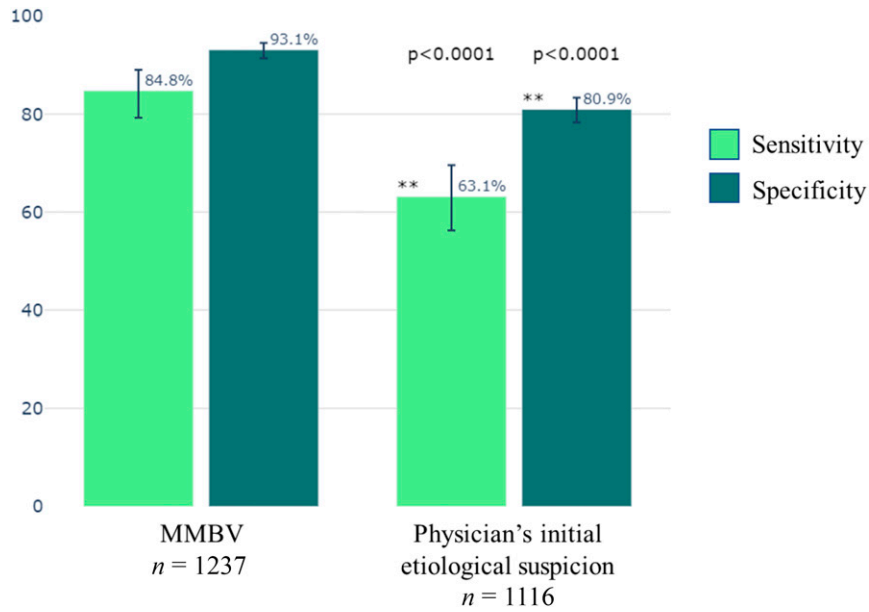
2. Suspected diagnosis:



Other possibilities: combination viral & bacterial/ not an infectious disease

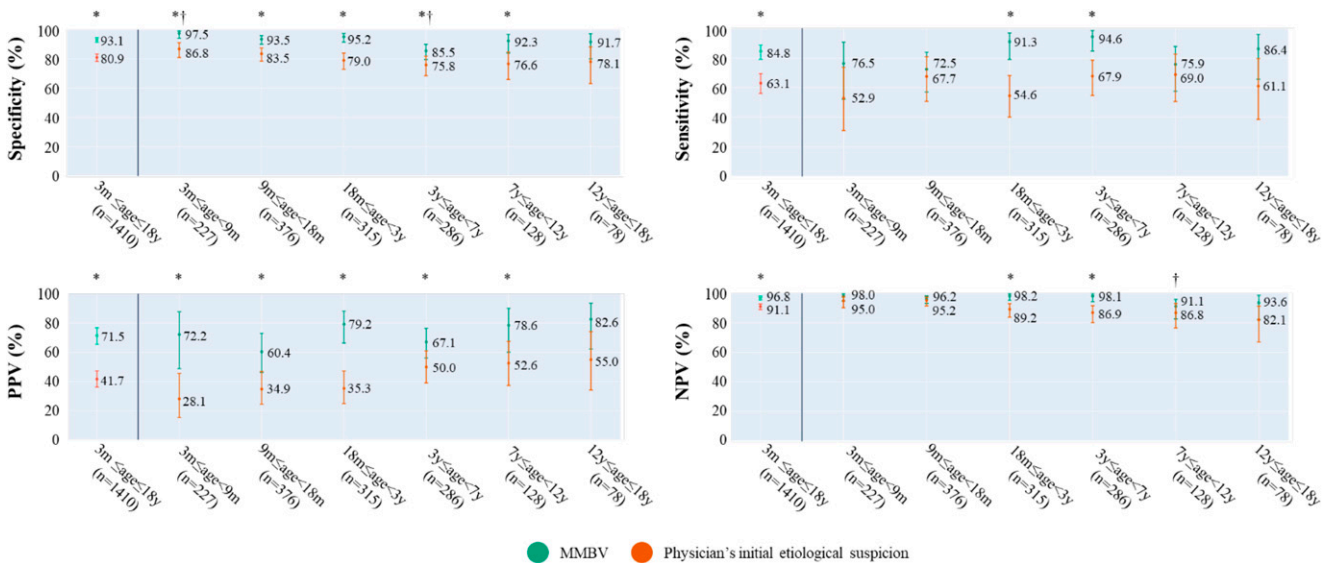
#### SUPPLEMENTAL FIGURE 1

Physician label questionnaire. A form filled in by the ED attending physician after obtaining medical history and physical examination, documenting the extent of available clinical information at the time of questionnaire completion (eg, laboratory tests, urinalysis). Physician's suspicion of clinical syndrome, initial etiologic diagnosis and degree of diagnostic certainty were documented.



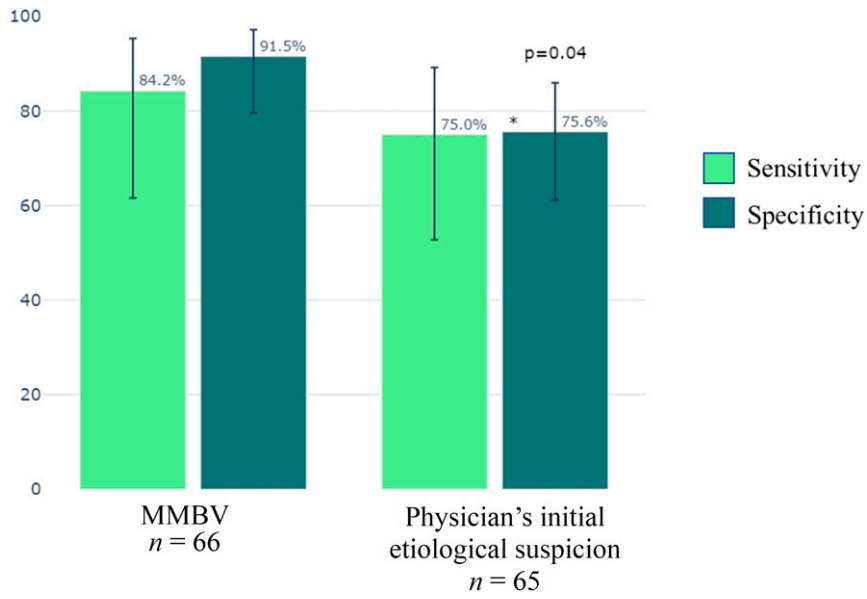
**SUPPLEMENTAL FIGURE 2**

Diagnostic accuracy of MMBV and physician's initial etiological suspicion (n = 1410). Out of the 1410 eligible cases, 1237 cases yielded a bacterial/viral MMBV result, and 1116 cases were assigned a bacterial/viral etiology by the physician. Error bars indicate 95% confidence intervals.



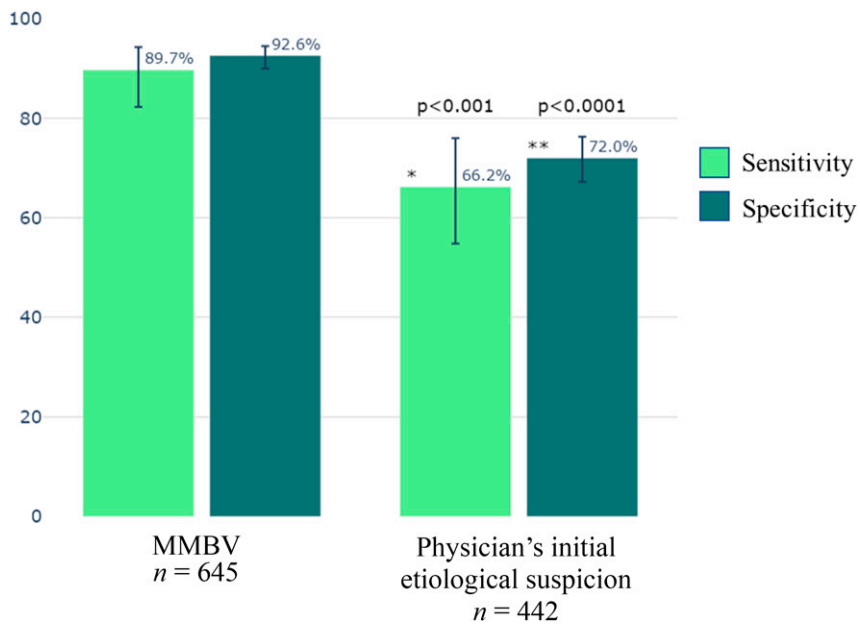
**SUPPLEMENTAL FIGURE 3**

Diagnostic accuracy of MMBV and physician initial etiological suspicion across age groups. Data are shown for the eligible patients for whom there was a bacterial or viral reference standard and a completed questionnaire. Error bars indicate 95% confidence intervals. \* Denotes P < .05 when comparing performance of MMBV to that of physician's initial etiological suspicion. † Denotes P < .05 when comparing MMBV performance for the specific age group to that of MMBV for all ages (n = 1410).



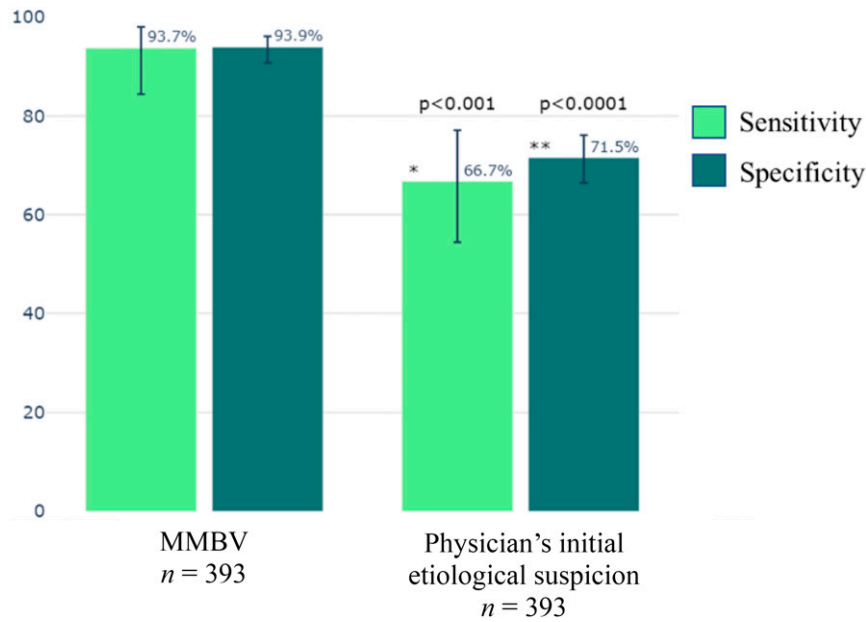
**SUPPLEMENTAL FIGURE 4**

Diagnostic accuracy of MMBV and physician initial etiological suspicion in patients in which laboratory tests were available ( $n = 76$ ). Out of 76 cases in which laboratory tests were available to the physician at the time the questionnaire was completed, 66 cases yielded a bacterial/viral MMBV result, and 65 were assigned a bacterial/viral etiology by the physician. Error bars indicate 95% confidence intervals.



**SUPPLEMENTAL FIGURE 5**

Diagnostic accuracy of MMBV and physician in the low certainty cohort ( $n = 736$ ). Out of the 736 cases that comprised the low certainty cohort, 645 cases yielded a bacterial/viral MMBV result, and 442 cases were assigned a bacterial/viral etiology by the physician. Error bars indicate 95% confidence intervals.



#### SUPPLEMENTAL FIGURE 6

Diagnostic accuracy of MMBV and physician's initial etiological suspicion in the low certainty cohort (paired cohort,  $n = 393$ ). Out of the 736 patients in the low certainty cohort, 393 patients received a bacterial/viral label from both MMBV and the physician. MMBV performed with sensitivity  $59/63 = 93.7\%$  and specificity  $310/330 = 93.9\%$ ; Physician performed with sensitivity  $42/63 = 66.7\%$  and specificity  $236/330 = 71.5\%$ . Error bars indicate 95% confidence intervals.

**SUPPLEMENTAL TABLE 1** Tests Ordered as Part of Routine Care

	Eligible Cohort ( $n = 2155$ )	Susp LRTI ( $n = 216$ )	Susp URTI ( $n = 712$ )	Susp FWS ( $n = 785$ )	Susp UTI ( $n = 110$ )	Susp Other ( $n = 168$ )	Missing Questionnaire ( $n = 164$ )
CRP, $n$ (%)	2155 (100.0%)	216 (100.0%)	712 (100.0%)	785 (100.0%)	110 (100.0%)	168 (100.0%)	164 (100.0%)
WBC, $n$ (%)	2148 (99.7%)	215 (99.5%)	709 (99.6%)	783 (99.7%)	110 (100.0%)	168 (100.0%)	163 (99.4%)
Cultures, $n$ (%)	2006 (93.1%)	202 (93.5%)	656 (92.1%)	727 (92.6%)	108 (98.2%)	156 (92.9%)	157 (95.7%)
Serology, $n$ (%)	279 (12.9%)	33 (15.3%)	94 (13.2%)	78 (9.9%)	9 (8.2%)	28 (16.7%)	37 (22.6%)
Chest radiograph, $n$ (%)	895 (41.5%)	174 (80.6%)	288 (40.4%)	261 (33.2%)	37 (33.6%)	51 (30.4%)	84 (51.2%)
US, $n$ (%)	290 (13.5%)	18 (8.3%)	60 (8.4%)	98 (12.5%)	51 (46.4%)	40 (23.8%)	23 (14.0%)
CT, $n$ (%)	46 (2.1%)	2 (0.9%)	12 (1.7%)	18 (2.3%)	2 (1.8%)	12 (7.1%)	0 (0.0%)
Lumbar puncture, $n$ (%)	48 (2.2%)	1 (0.5%)	8 (1.1%)	24 (3.1%)	1 (0.9%)	12 (7.1%)	2 (1.2%)
PCR, $n$ (%)	141 (6.5%)	28 (13.0%)	36 (5.1%)	34 (4.3%)	1 (0.9%)	9 (5.4%)	33 (20.1%)

CRP, C-reactive protein; WBC, white blood cells; US, ultrasound; CT, computed tomography; PCR, polymerase chain reaction; LRTI, lower respiratory tract infection; URTI, upper respiratory tract infection; FWS, fever without source; UTI, urinary tract infection.

**SUPPLEMENTAL TABLE 2** Patients With a Bacterial Reference Standard Label and a Viral MMBV Result (False Negative Cases; Low Certainty Cohort;  $n = 11$ )

Patient	MMBV	Reference standard	Sex	Age (y)	Discharge diagnosis	Max temp	Time from onset of symptoms (d)	Chronic conditions
Patient 8836	21	Bacterial	Female	4	Acute tonsillitis	40	0	None
	<b>Microbiology</b>			<b>ANC</b>	<b>CRP (mg/L)</b>	<b>Clinical details</b>		
	Group A strep			12.3	11	Presented with fever, cough and vomiting starting on the day of admission, initial physical examination was without significant findings, was hospitalized for evaluation with subsequent development of bilateral exudative tonsils, was hospitalized for 4 d and treated with amoxicillin.		
Patient 8842	5	Bacterial	Male	0.83	Septic arthritis	38.1	2	None
	<b>Microbiology</b>			<b>ANC</b>	<b>CRP (mg/L)</b>	<b>Clinical details</b>		
	kingella kingae, Staph coagulase negative			9.26	8.2	Presented with 2 d of fever, rash, mouth ulcers and limited limb movement, physical examination was significant for a limited hip movement, bilateral cervical lymphadenopathy and bilateral middle ear opacity, hip joint ultrasound and wrist x-ray results were normal, synovial fluid culture result from wrist was negative, was hospitalized for 10 d and treated with cefazolin IV.		
Patient 9007	6	Bacterial	Female	8	AOM	38.4	6	Otitis recurrent, Appendectomy S/P, Obesity
	<b>Microbiology</b>			<b>ANC</b>	<b>CRP (mg/L)</b>	<b>Clinical details</b>		
	<i>Pseudomonas A</i>			4.45	28.3	Presented with a 6-d history of fever and otodynia, physical examination was significant for right ear purulent discharge, was hospitalized for 6 d and treated with ceftazidime IV.		
Patient 9048	18	Bacterial	Male	1.08	Pneumonia	40.4	4	None
	<b>Microbiology</b>			<b>ANC</b>	<b>CRP (mg/L)</b>	<b>Clinical details</b>		
	None			13.57	65.7	Presented with a 4-d history of fever, cough and rhinorrhea, physical examination was significant for crepitations by auscultation and exudative tonsils, chest x-ray result was suspected consolidation in LUL, was discharged from the emergency department with amoxicillin treatment.		
Patient 9647	5	Bacterial	Male	1	Infectious mononucleosis	40	7	None
	<b>Microbiology</b>			<b>ANC</b>	<b>CRP (mg/L)</b>	<b>Clinical details</b>		
	EBV			6.19	41.8	Presented with a 7-d history of fever, rash, and neck swollenness, was already under a 72-h antibiotic treatment after arriving to the ED. Physical examination was significant for exudative tonsils and unilateral cervical lymphadenopathy, was hospitalized for 7 d and treated with cefazolin IV.		
Patient 9959	22	Bacterial	Male	9	Gastroenteritis	39.9	2	Febrile convulsions
	<b>Microbiology</b>			<b>ANC</b>	<b>CRP (mg/L)</b>	<b>Clinical details</b>		
	<i>Campylobacter Spp.</i>			8.89	74.3	Presented with a 2-d history of fever, abdominal pain and watery diarrhea, physical examination was significant for exudative tonsils, was hospitalized for 2 d and treated with amoxicillin.		

Patient	MMBV	Reference standard	Sex	Age (y)	Discharge diagnosis	Max temp	Time from onset of symptoms (d)	Chronic conditions
Patient 10081	0	Bacterial	Female	1.58	UTI	38.2	7	None
	<b>Microbiology</b>			<b>ANC</b>	<b>CRP (mg/L)</b>	<b>Clinical details</b>		
	E. coli			4.25	1.1	Presented with a 7-d history of fever, watery diarrhea and vomiting, physical examination was significant for rales on auscultation, and discharged from the emergency department with amoxicillin-clavulanate treatment.		
Patient 10216	0	Bacterial	Male	6	Acute Tonsillitis	39	1	Prematurity
	<b>Microbiology</b>			<b>ANC</b>	<b>CRP (mg/L)</b>	<b>Clinical details</b>		
	Group A strep			9.98	21.9	Presented with a 1-d history of fever, vomiting and convulsions on the day of admission, physical examination was significant for exudative tonsils, was hospitalized for 3 d and treated with amoxicillin.		
Patient 11047	10	Bacterial	Female	1	Pyelonephritis	39.9	0	None
	<b>Microbiology</b>			<b>ANC</b>	<b>CRP (mg/L)</b>	<b>Clinical details</b>		
	E. coli			10.2	34.6	Presented with fever and chills starting on the day of admission, had her MMRV vaccination in the past 2 wk, physical examination was normal, was hospitalized for 4 d and treated with gentamicin.		
Patient 11142	2	Bacterial	Male	0.83	Pneumonia	40	2	None
	<b>Microbiology</b>			<b>ANC</b>	<b>CRP (mg/L)</b>	<b>Clinical details</b>		
	None			22.62	101.1	Presented with a 2-d history of fever, chills, cough and rhinorrhea, physical examination was significant for rales on auscultation, chest x-ray result was suspected consolidation in RLL, was hospitalized for 4 d and treated with cefuroxime IV.		
Patient 11254	16	Bacterial	Female	1	UTI	39.4	1	None
	<b>Microbiology</b>			<b>ANC</b>	<b>CRP (mg/L)</b>	<b>Clinical details</b>		
	E. coli			13.2	45.8	Presented with 1-d history of fever and vomiting after a blunt head trauma, physical examination was significant for a papular rash, was discharged from the emergency department with amoxicillin-clavulanate treatment.		

ANC, absolute neutrophil count; CRP, C-reactive protein.